

A Histological Evaluation on The Protective Effect of Ethanolic Extract of Moringa Leaves on 4G-Cell Phone-Irradiated Testes of Wistar Rats

SUDHA RAMALINGAM¹ / Dr. X. CHANDRA PHILIP² / Dr. K.V.P. SURIYAKUMARI³

¹Tutor, Department of Anatomy, Sri Manakula Vinayagar Medical College and Hospital, Puducherry, India.

²Professor, Department of Anatomy, Mahatma Gandhi Medical College and Research Institute, Puducherry, India.

³Professor, Department of Anatomy, Sri Manakula Vinayagar Medical College and Hospital, Puducherry, India.

ABSTRACT

Introduction

Infertility is the growing problem in modern world. Fifty percent of infertility cases are paid for by the malefactor. Scientific researches revolve around the use of cell phones and infertility. Few studies have explored the effects of 2G, 3G and 4G-cell phone radiation on spermatogenesis and some other studies offer conflicting views. The aim of this research was to study the impact of electromagnetic radiation (EMR) on the testis of Wistar rats over a span of two months from a 4G mobile phone and to assess the potential radio-ameliorative efficiency of leaves of *Moringa oleifera* (MOL).

Materials and Methods

The male Wistar rats were divided into five groups. Control group (n=3) without mobile phone; Sham group (n=3) with mobile phone in switched-off mode; MOL-2 group (n=6) obtained oral 200 mg of ethanol extract of MOL /kg body weight for two months; R2 group (n=6) subjected to 4G-EMR for two months for 96 minutes/day; R2+MOL-2 (n=6) group exposed to EMR and treated concurrently with MOL extract for two months. After the experimental period, rats were sacrificed and testes were removed to analyze the morphometry and histological alterations.

Results

4G mobile phone-EMR caused a significant reduction in the length and thickness of the testis in the R2 group as compared to control, sham and MOL-2 groups. The ethanolic extract of MOL could not retrieve the variables to normal in the R2+MOL-2 group. But the extract retained the histo-morphology of the testes from the effects of 4G-EMR.

Conclusion

4G-LTE-radiation can influence spermatogenesis to some degree by adversely affecting the the histological aspect of the testes. Oral administration of ethanol extract of MOL will preserve the properties of testes from cell phones via the antioxidant properties of its phytochemicals.

Keywords: 4G-EMR; *Moringa Leaves*; *Morphometry*; *Testis*; *Histology*; *Antioxidants*.

Introduction

Male infertility has become a great concern nowadays. It is often connected with multiple environmental and occupational exposures.[1] Mobile phone technology reached a maximum peak of growth in the last decade. This technology is used by more than two-thirds of the global population for communication. The invention of the first-generation of the cell phone known as analog phone works at 450-900 MHz, the second-generation (digital phone) work at 850-1900 MHz [Global System for Mobile Communications, GSM], and the third-generation phone works at around 2000 MHz.[2] The prolonged use of a mobile phone affects the biological system of the body through radio frequency induced-electromagnetic radiation (RF-EMR) as non-ionizing radiation.[3,2] The production of RF-EMR depends on the frequency of the mobile phone handled. The greater the frequency, the higher the probability of more radiant energy being absorbed into the human body.[2] When using a hands-free tool such as Bluetooth, most men hold their mobile phones in a trouser pocket (or attached to the straps on their waist). This equipment exposes the testes to mobile phone radiation with a higher power density than a mobile phone in a trouser pocket in the 'Standby mode' Desai. Such RF-EMR can negatively influence the reproductive capacity of humans and animals. Various researchers documented the reproductive effects of RF-EMR as decreased primary spermatocyte and sperm count and abnormal sperm morphology. [3,2]

RF-EMR may disturb the bodily function by producing hyperthermia as thermal effects or through non-thermal effects like disrupting the plasma membrane of the cell; generating oxidative stress within the cell by increasing the output of reactive oxygen species (ROS) or by decreasing the antioxidant enzyme activity; causing DNA damage.[4]

Literature provided shreds of evidence that 2G and 3G mobile phone-radiations could cause detrimental effects on the male reproductive system.

Natural plants and plant products have gained a lot of attention because of their medicinal benefits owing to its high biocompatibility, low toxicity and significant biological activity in the treatment and prevention of different diseases.[5] *Moringa oleifera* is generally called a drumstick tree. Its root, pods, flower and leaves are used to treat various diseases from ancient times. They showed anti-cancer, anti-microbial, hepatoprotective properties.[6] As compared to other parts, its leaves have the maximum nutrient composition. They are a good source of protein, beta-carotene, vitamins A, B, C, and E, riboflavin, folic acid, nicotinic acid, amino acids, minerals, pyridoxine, and various phenolic compounds. The phenolic agents such as chlorogenic acid, quercetin, rutin and kaempferol possess high potential anti-oxidant activity against ROS-induced tissue damage. [7]

Several experiments demonstrated the radio-protective effect of *Moringa Oleifera* leaves (MOL) against gamma and cell phone radiations. Hence, this study aimed to evaluate the protective role of ethanolic extract of MOL against 4G mobile phone-RF-EMR-induced histological alteration in Wistar rats' testes.

Materials and methods

Animals

This research used four-week-old male Wistar rats, weighing approximately 150-180 gm, acquired from TANUVAS, Chennai. The animal experimentation procedures listed in this study were approved by the Institutional Animal Ethical Committee (Approval letter No. IAEC/2015/02, dated-14/05/2015). In compliance with the Guidelines of the Animal Ethical Committee for the Care and Use of Laboratory Animals, the rats were managed and used. They were housed in Plexiglas cages with a commercially available balanced diet and tap water ad libitum. They were subject to light and dark periods of 12 h/12 h and a temperature of 22 to 24°C.

After a week of acclimatization, rats were randomly divided into five groups. In similar settings, but each of them in a different EMR-free room, control and sham control groups were maintained.

Control group (n=3): No cell phone radiation.

Sham group (n=3): Exposed to the cell phone in switch off mode.

MOL-2 group (n=6): Received orally 200mg of ethanolic extract of *MOL* /kg body weight/day for two months.

R2 group(n=6): Exposed to EMR for 96 minutes/day for two months (4 minutes/every half an hour from 8 AM to 8 PM)

R2+MOL-2 (n=6): Exposed to EMR for 96 minutes/day (4 minutes/every half an hour from 8 AM to 8 PM) and concurrently treated orally with 200mg of ethanolic extract of *MOL*/kg body weight/day for two months.

The body weight was measured by automated weighing scales before the animals were sacrificed. Intraperitoneal injection of 45 mg/kg of ketamine hydrochloride was given 24 hours after the completion of the experiment to anesthetize the rats, accompanied by sacrifice. Testes were obtained by trans-abdominal incision and fixed for twenty-four hours in 4% Paraformaldehyde solution and processed and embedded in paraffin.

Cell phone-EMR System for exposure

This study used a typical commercial brand of Android cell phones with a whole-body SAR value of 1.6W/kg and a peak power density of 2W/kg (as stated by the manufacturer). The phones' average power density was 187.9 mW/m², which was measured using the Cornet Electromog RF meter from the electromagnetic field values of the inner aspect of the rat cage. It was approved for the service of 4G LTE pulse networks through BAND 5 LTE FDD (850 MHz), BAND 3 LTE FDD (1800 MHz), BAND 40 LTE TDD (2300 MHz). The smartphone was held in a box with a wood bottom measuring approximately 14 x 7 x 5 cm hanging from the roof of the cage of the rats to reach the middle of the cage; it was guaranteed (an equal distance of 7.6 cm from the bottom and roof of the cage) to have free movement of the animals.[8]

MOL collection and preparation of the extract

M. Oleifera leaves, authenticated by a Botanist, were harvested from a village in Cuddalore district, Tamil Nadu, India. The leaves were rinsed with water preceded by air and oven-dried at 44°C for four hours and powdered using an electric mixer grinder. The maceration method was used to produce the extract from the powdered leaves with 70% ethanol at a ratio of 1:40, w/v for 72 hours at room temperature with occasional shaking. The extract was filtered by no 1 Whatman filter paper and the remaining material was re-extracted by the same method and solvent till the marc was used fully.[9] Then, the solvent was eliminated by using the rotary evaporator and the final crude extract was stored at - 4°C for further use.

Morphometric measurement, weight and volume of testis

The length, breadth, thickness, weight and volume of the testicles were considered before preservation. The morphometric parameters were evaluated (in mm) using the Vernier caliper and the test weight was measured in grams using Denver's digital weighing machine. For the measurement of testis volume, the water displacement method was employed and the readings were expressed in ml.

Histopathological examination

For histo-morphological alteration, tissues were segmented at five microns and stained with Hematoxylin and Eosin (H&E). Hematoxylin and eosin-stained testicular sections from each rat were examined to identify the condition of tunica albuginea, seminiferous tubules, different kinds of cells in the germinal epithelium and interstitial area in all the groups.

Statistical analysis

The one-way analysis of variance (ANOVA) accompanied by a post hoc test (Tanhane/LSD) using JASP statistical software (University of Amsterdam, Netherlands) was employed to analyze the data. At P < 0.05, the differences were found to be statistically important.

Results

Baseline characteristics:

The body weight and testis weight are shown in Table 1 and these parameters did not differ significantly among the experimental groups. These results suggest that EMR may not alter the baseline variables of the rats. However, the volume of testis was insignificantly increased in EMR-rats and it was reduced significantly in the R2+MOL-2 group.

Table 1. The effect of ethanolic extract of MOL on body weight, testis weight and volume in the mobile phone-induced 4G-LTE-EMR exposed male rats.

| Parameters | Control | Sham | MOL-2 | R2 | R2+MOL-2 |
|------------------------|--------------|--------------|----------------|---------------|---------------|
| Body weight (gm) | 280±18.028 | 280±30.00 | 282.50± 24.648 | 257.50±44.469 | 280.83±40.794 |
| Testis weight (gm) | 1.553 ±0.123 | 1.546 ±0.126 | 1.593±0.085 | 1.535±0.062 | 1.486 ±0.080 |
| Testicular volume (ml) | 1.596±0.091 | 1.576±0.060 | 1.550±0.207 | 1.533±0.01211 | 1.560±0.12247 |

No significant differences were observed regarding the parameters between the groups.

Observations on morphometry of testes, weight and volume of testis

4G mobile phone-EMR caused a significant reduction in the length and thickness of the testis in the R2 group as compared to control, sham and MOL-2 groups. The ethanolic extract of MOL could not retrieve the variables to normal in the R2+MOL-2 group (table 2).

Table 2. The effect of ethanolic extract of MOL on length, breadth and thickness of testis in the mobile phone-induced 4G-LTE-EMR exposed male rats.

| Group | Control | Sham | MOL-2 | R2 | R2+MOL-2 |
|----------------|-----------------|--------------|--------------|--------------------------------|---------------------------------|
| Length (mm) | 20.135±0.703 | 19.700±0.856 | 20.661±0.437 | 18.57±0.606 ^{a, b, c} | 18.503±0.642 ^{a, b, c} |
| Breath (mm) | 11.43±0.618 | 11.45±0.571 | 11.671±0.394 | 11.5883±0.750 | 11.416±0.530 |
| Thickness (mm) | 10.0167±0.31252 | 9.720±0.533 | 10.275±0.562 | 8.430±0.543 ^{a, b, c} | 8.511±0.583 ^{a, b, c} |

Values are expressed as mean ± SD. Different superscript letters show significant differences between groups (P<0.0001). a- different from the control group; b- different from the sham group; c- different from the MOL-2 group.

Histopathological observations

Histopathologic analysis revealed only a few atrophic or wrinkled seminiferous tubules and tubules with detached epithelium; thickening of the basal lamina and tunica albuginea; interstitial edema and vascular congestion in testes of EMR-rats. On the other hand, 4G cell phone-RF-EMR affected the spermiation process at the VIII stage of the germ cell cycle. Many tubules showed unspemiated mature sperms still connected to the apical plasma membrane of the Sertoli cells in spermatogenic stages of IX, X and XI; engulfed unspemiated sperms at the basal cytoplasm of Sertoli cells for degradation at XI and XII stages (figure 3).

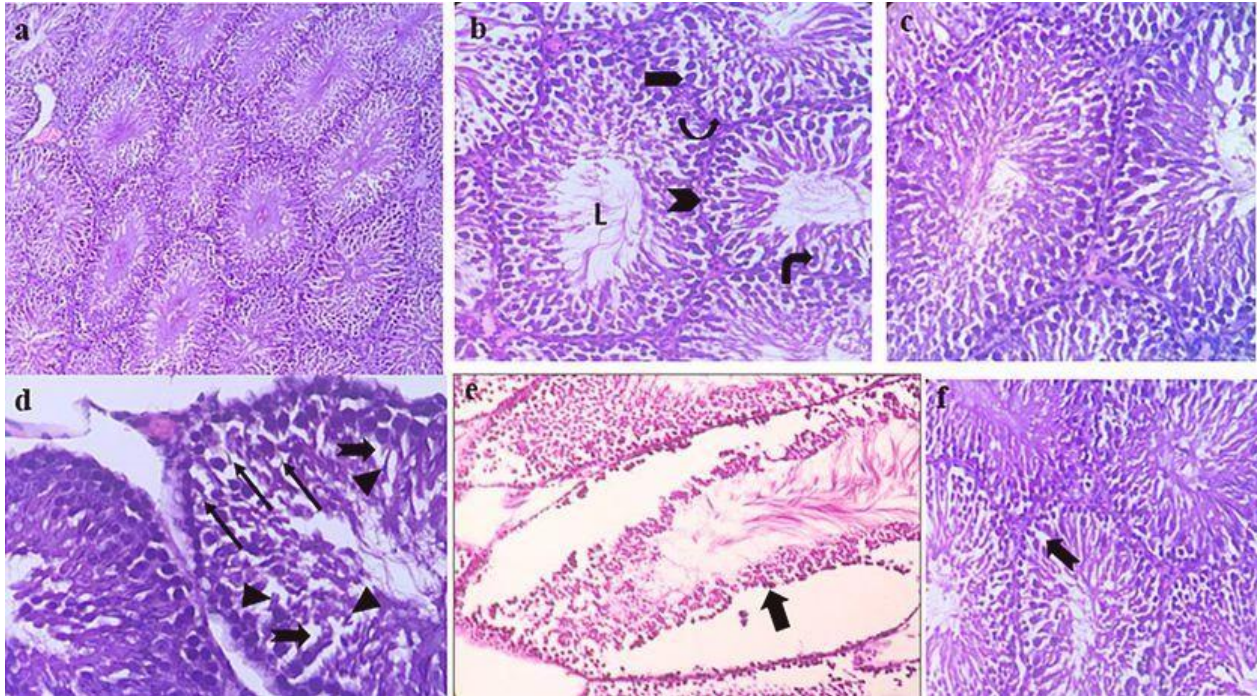


Figure 3. shows H&E stained microscopical view of testes of experimental rats. a) control rat testis showing normal histological pattern (100x). b) sham rat showing normal histology: C, Sertoli cell; ►, spermatogonium; ►, primary spermatocyte; ►, spermatids; L, lumen with mature sperm (400x). c) MOL-2 rat showing regular arrangement of germinal epithelium. d) R2 group showing altered histology (stage XI) ; ►, unpermiated mature sperm; ►, elongating spermatid; ►, empty space created by degenerated germ cell (400x). e) ►, detachment of the epithelium in a testis of R2 group (400x). f) R2+MOL group exhibiting near normal microscopic pattern of the testis but has empty space left by degenerated germ cell.

Discussion

The radiant energy emitted from the cell phone is absorbed by human body tissues by aerial effect or resonant absorption and/or combining the RF waves, which may alter the normal functional capacity of the testis. Recent developments in mobile phone communication technologies are coupled with a rise in signal strength, correlating with higher energy-radiofrequency signals. Thus, higher the frequency more the energy carried in the signals. The electrical and magnetic properties of the EMR induce the thermal and non-thermal effects on the human body by interacting with the biological system.[10]

Seminiferous tubules, Leydig cells and spermatozoa are the prime victims of destruction generated by mobile phones in the male reproductive system.[11] In the seminiferous epithelium, the high incidence of cell division and differentiation makes it incredibly susceptible to toxic substances during prepubertal life.[3]

In this study, exposure of 4G-LTE-EMR caused a reduction in the measurements of length and thickness of testis; treatment with MOL could not retain those parameters as that of control rats. But few histo-morphometric studies suggested that EMR can adversely affect the testis. Kumar et al., 2014 revealed that cell phones working on 1910.5 MHz can cause low sperm count, reduction in the diameter of the seminiferous tubules, testicular weight and DNA damage in rats in 60 days of EMR exposure.[12] Similarly, Kim et al., reported that 2.45 GHz EMF radiation with a power density of 50 mW/cm² for 2 hours/day/8 weeks could decrease the spermatocyte count.[3] Meo et al.,

2011 noted the whole-body exposure to mobile phone radiation for 60 min/day for 3 months produced hypo-spermatogenesis in 3 of 16 animals while another 3 had maturation arrest.[2] However, Lee et al., 2012 filed evidence that rats irradiated by whole-body exposure to CDMA (SAR-2.0 W/kg) and WCDMA (SAR-2.0 W/kg) RF signals simultaneously for 45 min/day, 5 days/week for 12 weeks cannot produce changes in the testes and epididymis, the number of spermatogenesis stages, and appearance of apoptotic cells in the testes as well as immunoblotting for p53, bcl2, GADD45, cyclin G, and HSP70. [13]

In this study, even though the testicular microscopic structure was not much disturbed, the existence of misshapen STs particularly underneath the capsule, inconsistent wider interstitial spaces, prominent vascular congestion and germinal epithelial vacuolization were seen under a light microscope (Figure 3). Similarly, Mugunthan et al., 2015 documented that 2G and 3G radiation treated mice testis showed detached Sertoli and germ cells; the presence of vacuolar degeneration and detachment of seminiferous epithelium; peripheral tubules with seminiferous epithelium showing a reduction in its thickness and hypo-spermatogenesis with low Johnson testicular biopsy score count in the first three month-EMR exposure.[14] Oh 2018 et. al suggested one-month duration of 4G cell phone-EMR exposure could reduce the germ cell count and Johnson's biopsy score in rats.[15] On the contrary, Celik et al., 2012 reported that only through the electron microscope, the thickness of membrane propria and increased collagen fiber contents and dilated capillary veins in the experimental group were noted.[16]

Scientific studies indicate that spermiation failure happens due to decreased serum testosterone or Sertoli cell toxicants in stage IX-XII of the sperm cycle. This may be the clinical parameter for spermatogenic obliteration and a significant cause for spermatogenic failure.[17] The sperm head retention at stage IX-XI in this study can be due to a reduction of testosterone which presumably responsible for the enhanced number of tubules with luminal and basal spermatid head retention in the EMR group. It suggests that 4G cell phone-EMR can damage the structure and function of Leydig cells.

Literature has shown that some of the MOL's micronutrients are stronger antioxidants that can act against free radical caused-tissue damage. The antioxidant phytochemicals present in MOL such as phenols and flavonoids can harvest free radicals or chelate Fe³⁺, resulting in radical to non-radical conversion or prevention of Fenton-like reaction leading to inhibition of tissue damage caused by the free radicals.[18] Tahoun et al., showed testicular, epididymal and serum testosterone levels were almost normalized using *Moringa oleifera*'s aqueous leaf extract against metronidazole-induced testicular damage.[5] Similarly, El-Wassimy et al., demonstrated the ability of *M. oleifera* leaf extract in protecting the rat testis against Dexamethasone-induced spermatogenic defects.[7] The antioxidant activity of MOL has been well documented against heavy metals-caused functional alteration of testis.[6] Furthermore, few researchers showed the potential of MOL in protecting tissues from ionizing radiation. MOL has been shown to have an important radioprotective effect on the bone marrow chromosomes of mice exposed to whole-body gamma radiation by Rao et al. [19] Pre-treatment with MOL could increase the level of superoxide dismutase, catalase, reduced glutathione and fluorescence recovery to protect the liver from γ -GR-induced damage.[20] A study explored the protective effect of MOL against cell phone radiation wherein concurrent treatment of 200 mg/kg aqueous extract of MOL prevented rats' testes from having irregular seminiferous tubules, few spermatogonia, multinucleated giant cells, degenerated spermatozoa and reduced number of Leydig cells and low PCNA labeling indices during 900 MHz cell phone-EMR exposure.[21] In the present study, the ethanolic extract of MOL retained the histological aspect of the testes as those of control rats which may be attributed to the free radical scavenging ability of MOL.

Conclusion

4G-LTE-radiation can influence spermatogenesis by negatively affecting the spermiation process and histological aspect of the testes to some extent. The oral administration of ethanolic extract of MOL can protect the characteristics of testes from 4G-LTE-EMR from a cell phone through the antioxidant ability of its phytochemicals.

References

1. Kesari K, Kumar S, Behari J. Effects of Radiofrequency Electromagnetic Wave Exposure from Cellular Phones on the Reproductive Pattern in Male Wistar Rats. *Applied Biochemistry and Biotechnology*. 2011;164(4):546-559.
2. Meo SA, Arif M, Rashied S, Husain S, Khan MM, Vohra MS, et al. Hypospermatogenesis and Spermatozoa Maturation Arrest in Rats Induced by Mobile Phone Radiation. *Journal of the College of Physicians and Surgeons Pakistan*. 2011; 21(5):262-265.
3. Kim JY, Kim HT, Moon KH, Shin HJ. Long-Term Exposure of Rats to a 2.45 GHz Electromagnetic Field: Effects on Reproductive Function. *Korean J Urol*. 2007; 48:1308-1314.

4. Desai N, Kesari K, Agarwal A. Pathophysiology of cell phone radiation: oxidative stress and carcinogenesis with focus on male reproductive system. *Reproductive Biology and Endocrinology*. 2009;7(1):114.
5. Tahoun EAEM. Protective Effect of *Moringa Oleifera* against Metronidazole-induced toxicity in male albino rats. *Journal of Bioscience and Applied Research*, 2017, Vol.3, No.2, 137-149
6. Ajilore BS and Atere TG. Effects of *Moringa oleifera* on total protein and lactate dehydrogenase level in testiculotoxic rats treated with cadmium chloride. *Res. J. of Health Sci*. 2014; 2(4).
7. El-wassimy M, El Haliem N, Hegazy M, Younes S, Al-Badry H. Possible protective effect of *Moringa oleifera* leaf extract on dexamethasone-induced histological changes in adult rat testes. *The Egyptian Journal of Histology*. 2014;37(1):112-123.
8. Narayanan S, Kumar R, Potu B, Nayak S, Mailankot M. Spatial memory performance of wistar rats exposed to mobile phone. *Clinics*. 2009; 64(3):231-234.
9. Vongsak B, Sithisarn P, Mangmool S, Thongpraditchote S, Wongkrajang Y, Gritsanapan W. Maximizing total phenolics, total flavonoids contents and antioxidant activity of *Moringa oleifera* leaf extract by the appropriate extraction method. *Industrial Crops and Products*. 2013; 44:566-571.
10. Bhat MA. Effects of Electromagnetic Waves Emitted by Mobile Phones on Male Fertility. *Computer Engineering and Intelligent Systems*. 2013;4(3).
11. La Vignera S, Condorelli R, Vicari E, D'Agata R, Calogero A. Effects of the Exposure to Mobile Phones on Male Reproduction: A Review of the Literature. *Journal of Andrology*. 2011;33(3):350-356.
12. Kumar S, Nirala JP, Behari J, Paulraj R. Effect of electromagnetic irradiation produced by 3G mobile phone on male rat reproductive system in a simulated scenario. *Indian Journal of Experimental Biology*. 2014;52:890-897.
13. Lee H, Jin Y, Kim T, Pack J, Kim N, Choi H et al. The effects of simultaneous combined exposure to CDMA and WCDMA electromagnetic fields on rat testicular function. *Bioelectromagnetics*. 2012;33(4):356-364.
14. Mugunthan N, Anbalagan J, Shanmuga Samy A, Rajanarayanan S, Meenachi S. Effects Of Chronic Exposure To 2G And 3G Cell Phone Radiation On Mice Testis – A Randomized Controlled Trial. *Int J Cur Res Rev*. 2015;7(4).
15. Oh J, Byun S, Lee S, Choe G, Hong S. Effect of Electromagnetic Waves from Mobile Phones on Spermatogenesis in the Era of 4G-LTE. *Bio Med Research International*. 2018; 1-8.
16. Çelik S, Aridogan IA, Izol V, Erdog̃ S, Polat S, Doran S. An Evaluation of the Effects of Long-term Cell Phone Use on the Testes Via Light and Electron Microscope Analysis. *Urology*. 2012;79(2):346-350.
17. Saito K, O'Dennel L, McLachlan RI, Robertson DM. Spermiation Failure Is a Major Contributor to Early Spermatogenic Suppression Caused by Hormone Withdrawal in Adult Rats. *Endocrinology*. 2000; 141(8):2779-2785.
18. Singh B, Singh B, Singh R, Prakash D, Dhakarey R, Upadhyay G et al. Oxidative DNA damage protective activity, antioxidant and anti-quorum sensing potentials of *Moringa oleifera*. *Food and Chemical Toxicology*. 2009;47(6):1109-1116.
19. Rao AV, Uma Devi P, Kamath A. In vivo radioprotective effects of *Moringa oleifera* leaves. *Indian Journal of Experimental Biology*. 2001;39:858-863.
20. Sinha M, Das D, Bhattacharjee S, Majumdar S, Dey S. Leaf Extract of *Moringa oleifera* Prevents Ionizing Radiation-Induced Oxidative Stress in Mice. *Journal of Medicinal Food*. 2011;14(10):1167-1172.
21. Bin-Meferij MM, El-Kott AF. The radioprotective effects of *Moringa oleifera* against mobile phone electromagnetic radiation-induced infertility in rats. *Int J Clin Exp Med*. 2015; (8):12487-12497.